

# Category:Cardiology

## Pages in category "Cardiology"

The following 200 pages are in this category, out of 307 total.

(previous page) (next page)

-

- Arterial Catheter

### 3

- 3.2 ECG

### A

- ABO system (English)
- Abdominal aorta
- Abdominal aortic aneurysm
- Acquired heart defects
- Acute myocardial infarction
- Adam Stokes syncope
- Agents of cardiovascular infections
- Amplatzer's occluder
- Aneurysm
- Angina pectoris
- Angioinvasive Treatment Arterial Occlusion and Stenosis
- Angioinvasive treatment of arterial blockages and stenoses
- Angiotensin converting enzyme inhibitors
- Angiotensin II receptor blockers
- Ankle pressure index
- Antiaggregation
- Anticoagulants
- Antiplatelet medications
- Aorta abdominalis
- Aorta thoracica
- Aortic regurgitation
- Aortic stenosis
- Aortic Valve Stenosis
- Aquaretics
- Arrhythmias (pediatrics)
- Arrhythmic storm
- Arrhythmogenic cardiomyopathy
- Arterial examination
- Arterial hypertension
- Arterial reconstruction
- Arterial Reconstruction
- Arteriosclerosis
- Artery examination
- Artery reconstruction
- Assessment of total cardiovascular risk
- Atherosclerosis
- Atrial Fibrillation
- Atrial fibrillation
- Atrial flutter
- Atrial septal defect
- Automated external defibrillators

### B

- Bathmotropism
- Bicuspid Aortic Valve
- Biochemical Diagnosis of Myocardial Infarction
- Biochemical examinations in acute myocardial infarction
- Biochemical indicators of acute myocardial infarction
- Blood Pressure
- Blood pressure measurment
- Blood pressure regulation

- Blood supply of the heart
- BMI
- Bradyarrhythmia
- Bradyarrhythmias and Bundle branch blockages
- Bradycardia
- Brugada syndrome
- Bypass

## C

- Calcium channel blockers
- Cardiac conduction system
- Cardiac cycle
- Cardiac inflammations (pediatrics)
- Cardiac markers
- Cardiac muscle contraction
- Cardiac Output
- Cardiac sarcoidosis
- Cardiac silhouette
- Cardiac Syndrome X
- Cardiac tamponade
- Cardiac tamponade (pediatrics)
- Cardiac tamponade (pediatrics)
- Cardiogenic shock
- Cardiogenic shock (CS)
- Cardiogenic shock (pediatrics)
- Portal:Cardiology
- CHA2DS2-VASc score
- Wells' score
- Cardiomegaly
- Cardiomyopathies
- Cardiomyopathy (CM)
- Cardioplegia
- Cardiotonics
- Cardiovascular disease in the elderly
- Carotid artery dissection
- Causes of circulatory insufficiency in the heart
- Central cyanosis
- Central venous pressure
- CHA2DS2 - VASc score
- Chronic ischemic disease of the lower limbs
- Chronotropy
- Circulatory collapse
- Classification of shock (pediatrics)
- Clinical signs of shock (pediatrics)
- Clubbed fingers
- Coarctation of the aorta
- Congenital Heart Defects
- Congenital thrombophilia
- Constrictive pericarditis
- Contraction of the heart muscle
- Contrast echocardiography
- Coombs murmur
- Cor pulmonale
- Coronary Blood Flow
- Coronary circulation
- Cystic medial necrosis
- Cystic medionecrosis

## D

- Defibrillation
- Defibrillation and cardioversion 2
- Determination of cardiac output
- Diagnostic imaging methods during chest examination
- Diagnostic use of ultrasound
- Diastolic blood pressure
- Differential diagnosis of chest pain/PGS (VPL)
- Differential diagnosis of dyspnea/PGS (VPL)
- Differential diagnosis of lower limb swelling
- Dilated cardiomyopathy
- Dilated cardiomyopathy (pediatrics)
- Direct vasodilation
- Dissection of the thoracic aorta
- Distal diuretics

- Distributional shock (pediatrics)
- Diuretics
- Doppler echocardiography
- Dressler's syndrome
- Dromotropia
- Dromotropy
- Dyspnea

## E

- Ebstein anomaly
- ECG examination
- ECG Leads
- Echocardiography
- Economy class syndrome
- Effect of drugs on heart rhythm
- Effect of poisons on heart rhythm
- Effects of poisons on heart rhythm
- Electrical cardioversion
- Electrocardiogram
- Electrocardiogram manifestations of disturbances of impulse generation and conduction
- Electrocardiography
- Electrocardiography (2. LF UK)/Evaluation
- Electrocardiography 2 (2. LF UK)
- Embolism
- End-diastolic volume
- Endocarditis
- Endocardium
- Endomyocardial biopsy
- Epicardium
- Examination of the arteries
- Examination of the child's cardiovascular system
- Examination of the child's cardiovascular system
- Extrasystole

## F

- Fallot's tetralogy
- Fats in diet
- Fibrinolytic system
- Foramen ovale patens

## G

- Gestational cardiomyopathy

## H

- HAS-BLED score
- Head-up tilt test
- Heart
- Heart Autorhythmicity
- Heart failure (internal)
- Heart failure/Repetitorium
- Heart inflammation
- Heart murmurs
- Heart rate
- Heart rhythm disorders
- Heart rhythm disorders (neonatology)
- Heart Tumors
- Heart valves
- Heart whirl
- Heparin
- Home blood pressure monitoring
- Hypertension (paediatrics)
- Hypertrophic cardiomyopathy
- Hypertrophic cardiomyopathy/diagnosis
- Hypertrophic cardiomyopathy/treatment
- Hypolipidemic treatment
- Hypotension
- Hypovolemic shock (pediatrics)

## I

- Infarct
- Infective endocarditis (pediatrics)
- Intraaortic balloon counterpulsation
- Invasive blood pressure monitoring (pediatrics)
- Ion exchangers
- Ischemic changes on the electrocardiogram
- Ischemic heart disease

## K

- Kalium-sparing diuretics
- Kent's cluster
- Keshan disease

## L

- Left bundle branch block
- Left cardiac catheterization
- Left heart failure

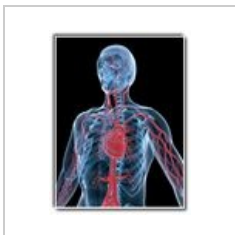## M

- Malignant arrhythmia
- Marfan syndrome
- Maze
- Mean arterial pressure
- Measurements of the Cardiac Output
- Metoprolol
- Migrating thrombophlebitis
- Migratory thrombophlebitis

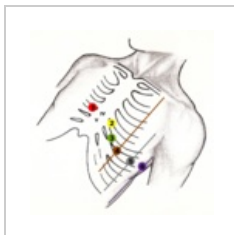
(previous page) (next page)

## Media in category "Cardiology"

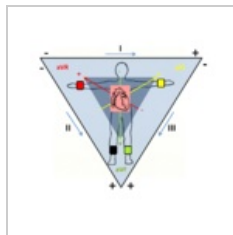
The following 7 files are in this category, out of 7 total.



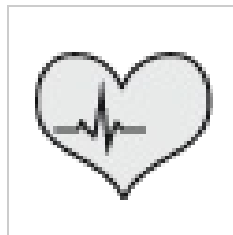Blood circulation....  
333 × 433; 87 KB



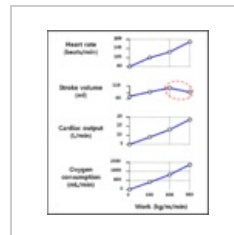
Chest leads.png  
2,058 × 2,070;  
4.55 MB



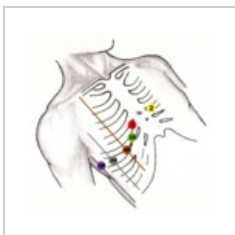Einthoven.png  
1,931 × 1,717;  
1.26 MB



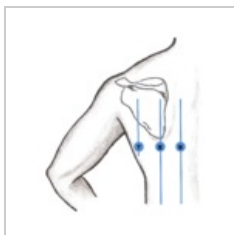
Kardiologie.png  
50 × 50; 4 KB



Sportsphysiology...  
750 × 857; 33 KB



V3R-V6R.png  
2,081 × 2,069; 4.6  
MB



V789.png  
1,684 × 1,844; 1.5  
MB