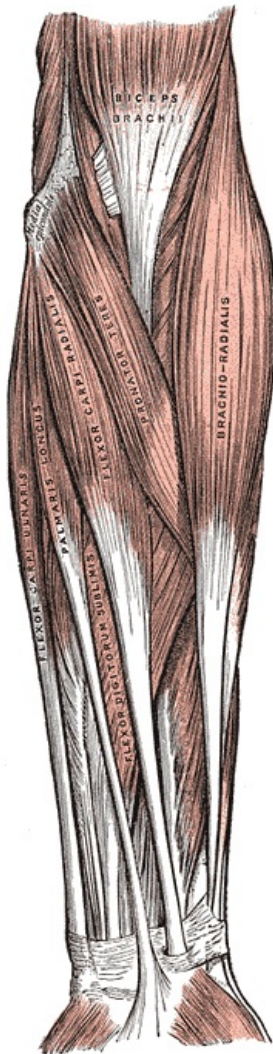


Cubital Fossa



Boundaries of the cubital fossa

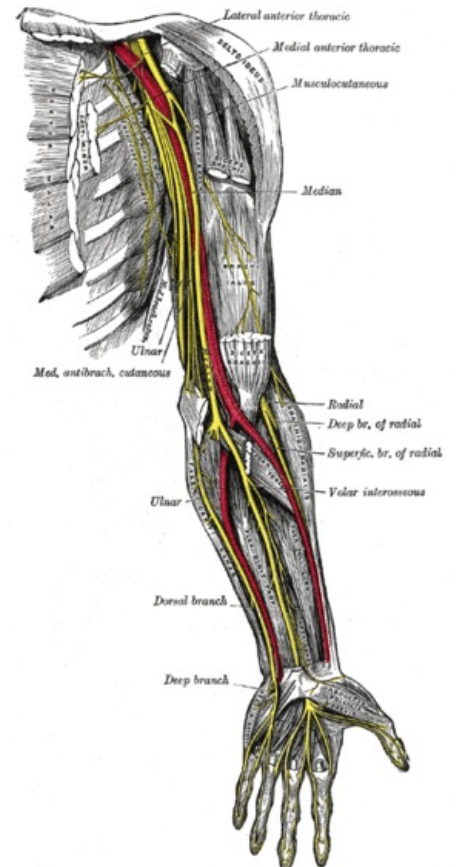
Boundaries of the cubital fossa

- Base - this is an imaginary line joining the two epicondyles of the humerus
- Medial border (ulnar) - pronator teres muscle
- Lateral border (radial) - brachioradialis muscle
- Roof - consist of fascia. superficial nerves and blood vessels are found here, covered by skin.
- Floor - medially: brachialis and laterally: supinator

Contents

- The radial nerve (between brachioradialis and brachialis)
- The brachial artery (bifurcates into the radial artery (superficial) and ulnar artery (deeper)) and the brachial vein
- The median nerve
- one can also use the mnemonic for lateral to medial: "Really Need Beer To Be At My Nicest". (radial n., bicipital tendon, brachial a., median n.)

The ulnar nerve is also in the area, but is not in the cubital fossa; it occupies a groove on the posterior aspect of the medial epicondyle of the humerus. Several veins are also in the area (for example, the median cubital vein, cephalic vein, and basilic vein) but these are usually considered superficial to the cubital fossa, and not part of its contents.



Content of the cubital fossa

Links

Bibliography

- PETROVICKY, Pavel, et al. *Anatomie s topografií a klinickými aplikacemi : Sv. 1, Pohybové ústrojí. 1.* edition. Martin : Osveta, 2001. 463 pp. ISBN 80-8063-046-1.
- J. H. Meiring et al, 1993, ANATOMY, 1st edition, Pretoria, Van Schaik, pg 147, ISBN 0 86874 454 9