

Carpal Tunnel

English: *Carpal tunnel*

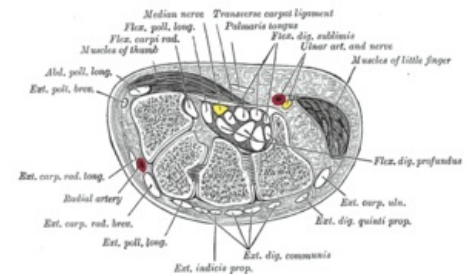
Latin: *Canalis carpi*



The **carpal tunnel** is the space between the flexor retinaculum and the carpal bones.

Contents

- The median nerve;
- The tendons of the flexor digitorum superficialis. (4 muscles);
- The tendons of the flexor digitorum profundus (4 muscles);
- The tendon of the flexor pollicis longus;
- The tendon of the Flexor carpi radialis.



Carpal tunnel

The median nerve lies in between the flexor digitorum superficialis and flexor digitorum profundus.

The carpal tunnel is very narrow, if there is a narrowing of the tunnel due to muscle swelling it can compress and trap the median nerve; this is also known as carpal tunnel syndrome.

Links

Related articles

- Carpal tunnel syndrome

Bibliography

- PETROVICKY, Pavel, et al. *Anatomie s topografií a klinickými aplikacemi : Sv. 1, Pohybové ústrojí. 1.* edition. Martin : Osveta, 2001. 463 pp. ISBN 80-8063-046-1.