

Radial Fossa

English: *Radial fossa*
Latin: *Foveola radialis*



The **anatomical snuffbox** (**radial fossa**, lat. *foveola radialis*);

- the posterior border – the tendon of the extensor pollicis longus;
- the anterior border – tendons of the extensor pollicis brevis and the abductor pollicis longus.

Contents:

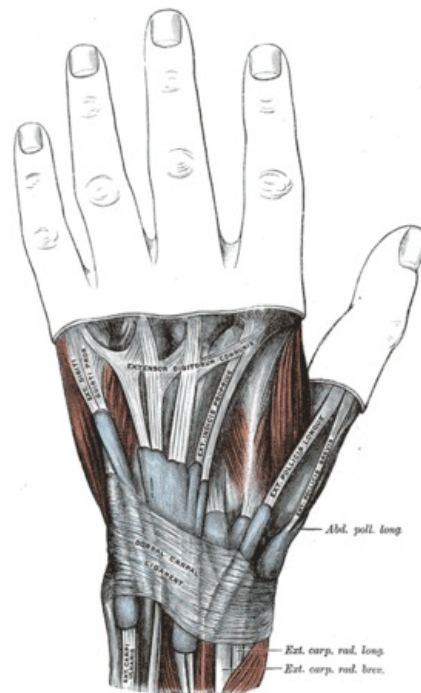
- the radial artery;
- the dorsal cutaneous branch of the radial nerve;
- the cephalic vein.

Note: It is possible to palpate the fracture of the scaphoid bone here.

Links

Bibliography

- PETROVICKY, Pavel, et al. *Anatomie s topografií a klinickými aplikacemi : Sv. 1, Pohybové ústrojí*. 1. edition. Martin : Osveta, 2001. 463 pp. ISBN 80-8063-046-1.



Fossa radialis