

# Suprapiriform Foramen

**English:** *Suprapiriform foramen*

**Latin:** *Foramen suprapiriforme*



The **suprapiriform foramen** (lat. *foramen suprapiriforme*) is bounded by the **greater sciatic notch** (*incisura ischiadica major ossis coxae*), the **sacrotuberous ligament** (*ligamentum sacrotuberale*) and **piriform muscle** (*musculus piriformis*). It is a part of the greater sciatic foramen (*foramen ischiadicum majus*) and it contains:

- superior gluteal nerve
- superior gluteal vessels

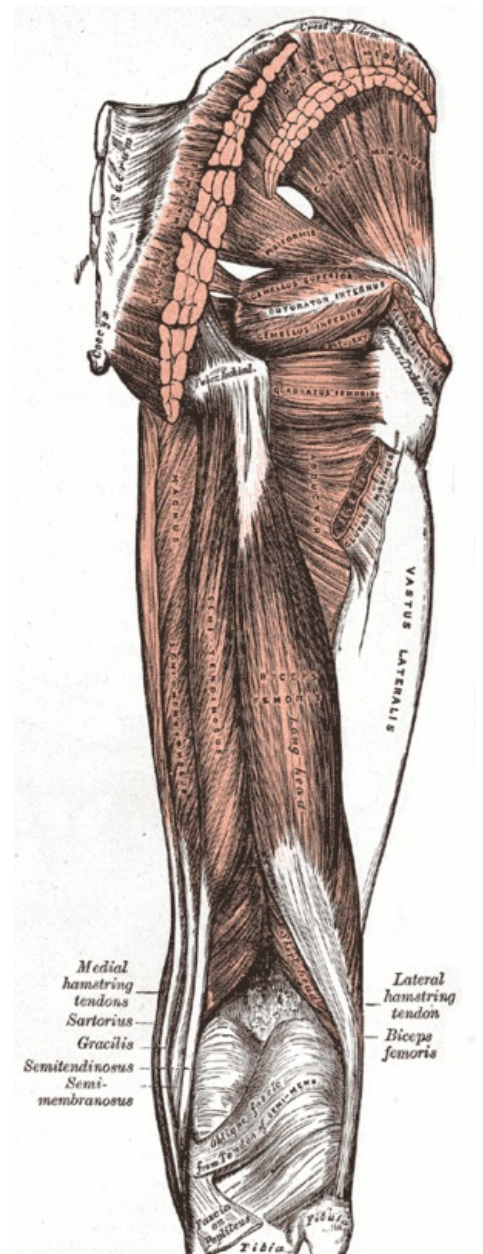
## Links

### Related articles

- Infrapiriform Foramen

### Bibliography

- PETROVICKY, Pavel, et al. *Anatomie s topografií a klinickými aplikacemi : Sv. 1, Pohybové ústrojí. 1.* edition. Martin : Osveta, 2001. 463 pp. ISBN 80-8063-046-1.



Foramen suprapiriforme